

URACHUS: A LITERATURE REVIEW

Zahri A. Rani

Urology Department, Faculty Of Medicine, Universitas Syiah Kuala, Indonesia

Said A. Khalilullah

Urology Department, Faculty Of Medicine, Universitas Syiah Kuala, Indonesia

Reza Maulana*¹

Urology Department, Faculty Of Medicine, Universitas Syiah Kuala, Indonesia

Email : reza.maulana@usk.ac.id

INTRODUCTION

The urachus is the result of allantois obliteration. Failure to obliterate the allantois results in various urachal anomalies, some of which can cause clinical manifestations. Typical clinical symptoms in children are periumbilical fluid (42%), umbilical mass (30%), abdominal or periumbilical pain (22%), and rarely dysuria (2%).¹ Clinical symptoms in adults include umbilical drainage, umbilical mass, omphalitis, cyst infection, abdominal pain, hematuria, dysuria, and may be asymptomatic.²

Urachus is a relatively rare pathological condition. The incidence of patent urachus in children is reported to be about 1 in 5,000 live births. Urachus in adults is usually found between the ages of 20-40 years, more often in men than women with a ratio of about 2:1. Urachal anomalies can cause problems, especially if complications occur such as infection, rupture of the urachal cyst, malignant development, and others.²

Urachus is classified into two types, inverted tunnel type and tubular type. The most common type of urachus is the inverted tunnel type (84%). The tubular type occurs in 16% of all cases.³

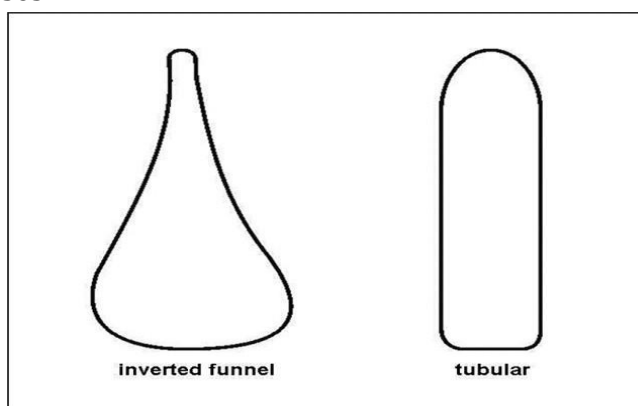


Figure 1. Types of Urachal Shapes

¹ Corresponding author.

From an embryological history, the urachus is an extraperitoneal structure. In adulthood, the fibrotic tract is located along the lower part of the posterior rectus sheath. The size of the urachus varies. Its length ranges from 3 to 10 cm and its diameter are about 8 to 10 mm. The urachus can join one or two umbilical arteries that have undergone obliteration and a slight deviation to the right or left of the body's midline axis.⁴

Types of Urachal Anomalies

1. Patent Urachus

Patent urachus occurs due to failure of obliteration of the epithelium lining the urachal canal. It is thought to be caused by obstruction of the urinary bladder during the intrauterine period. Another theory states that retubularization is the cause of urinary drainage through the umbilicus. Clinically, patent urachus can be suspected if there is continuous or intermittent fluid drainage from the umbilicus.⁵

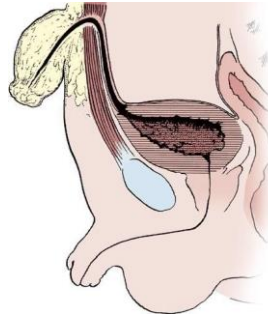
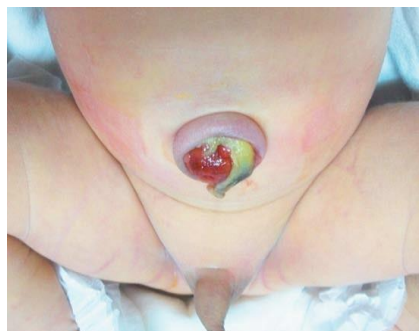

Figure 2. The development of patent urachus.



The clinical presentation of patent urachus is umbilical drainage, edematous or swollen umbilicus, and slow healing of the cord stump. Diagnosis is confirmed by the presence of a fluid-filled canal on longitudinal ultrasound examination, retrograde contrast fistulography examination, or voiding cystourethrography (VCUG) examination.⁵

2. Umbilical-Urachal Sinus

In umbilical-urachal sinus, the urachus undergoes obliteration at the level of the urinary bladder but remains open at the umbilicus, causing a draining sinus. Its presentation is similar to patent urachus. Diagnosis is made with a sinogram. The

caudal part of the urachus is filled with desquamated epithelial cells and is not related to the urinary bladder.⁵

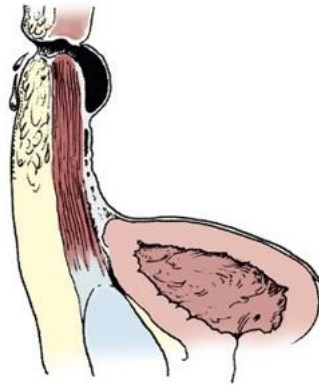


Figure 4. Embryological process of umbilical-urachal sinus

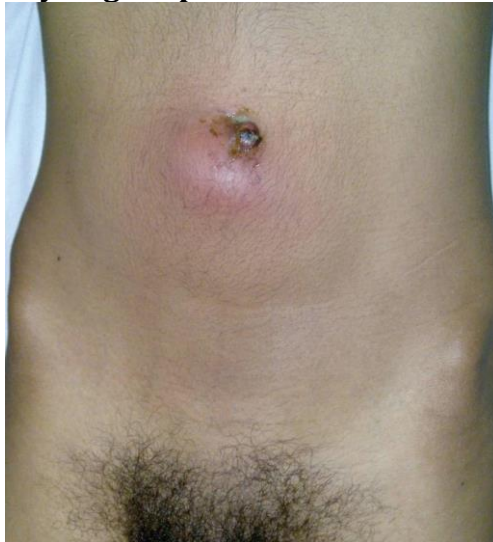

Figure 5. Picture of urachal sinus infection

3. Urachal Cysts

In urachal cysts, there is no connection between the cyst and the urinary bladder or umbilicus. However, drainage to the urinary bladder or umbilicus can sometimes occur. Most urachal cysts occur in the distal third of the urachus due to epithelial desquamation and degeneration, and are more commonly found in adults than in infants and children.⁶

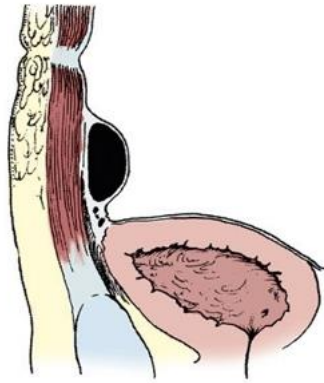
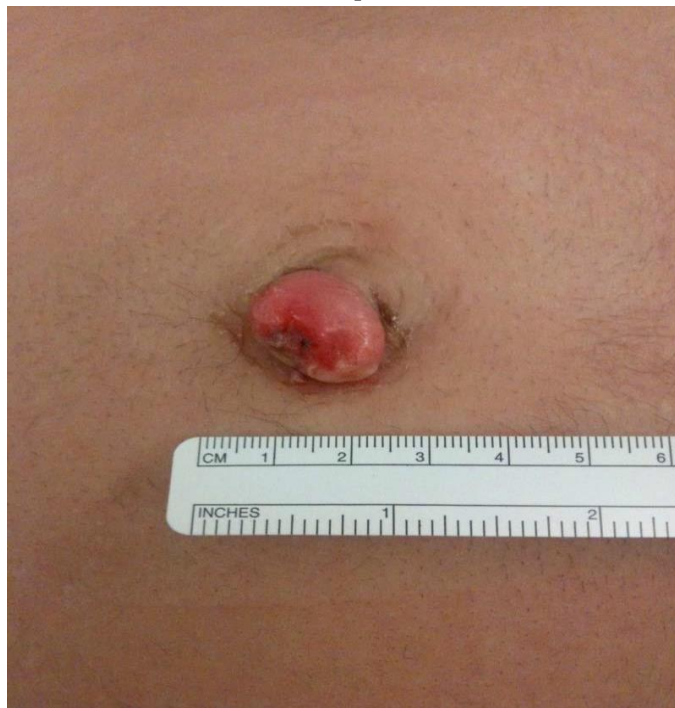

Figure 6. The process of urachal cyst formation.

The clinical presentation of urachal cysts is non-specific. Urachal cysts can enlarge without causing clinical symptoms. The cyst contains desquamated epithelial cells that can become infected. *S. aureus* is the most common organisms responsible for these infections. Urachal cysts only cause clinical symptoms when infected. The symptom triad for an infected urachal cyst is a painful infraumbilical mass, pus from the umbilicus, and sepsis.⁶



4. Vesicourachal Diverticulum

In vesicourachal diverticulum, the urachus undergoes almost complete obliteration, except at the apex of the urinary bladder. This lesion is usually asymptomatic and found incidentally on radiographic examination. Although the diverticulum can enlarge due to urinary obstruction, it rarely causes problems

because the diverticulum has a wide path to the urinary bladder. Diverticulum can cause stone formation and urinary tract infections, especially if the diverticulum neck is narrow. In infants, vesicourachal diverticulum is generally associated with Prune-Belly syndrome.

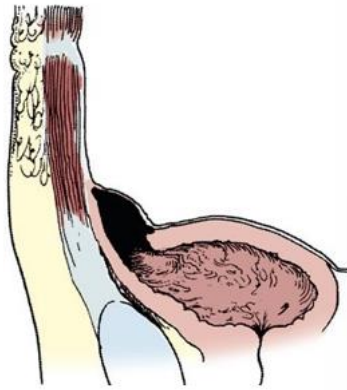


Figure 8. Vesicourachal diverticulum.

Clinical Manifestations

Clinical symptoms of urachal anomalies include asymptomatic, abdominal pain, fever, periumbilical mass, urinary tract infection, and discharge.⁷ Discharge can be clear, serous, purulent, or bloody. Clear discharge that resembles urine is strongly suspected to be from a patent urachus. While discharge that is serous, purulent, or bloody is suspected to originate from a sinus or cyst.⁸

Abnormalities found on physical examination of urachal anomalies include:⁸

1. Patent urachus: intermittent umbilical flow in the form of serum or urine.
2. Urachal sinus: intermittent umbilical flow in the form of serous or serosanguinous fluid.
3. Urachal cyst: No flow is found at the umbilicus. But with an infected cyst, on physical examination, both an infraumbilical or suprapubic mass is found, and erythema on the skin surface.
4. Vesicourachal diverticulum: No mass or flow is found at the umbilicus.

Radiological examination for the urachus includes VCUG, fistulography, ultrasonography, CT scanning, and MRI. The choice of modality is tailored to the type of urachal anomaly. Patent urachus can be clearly seen with fistulography and VCUG. Urachal sinus can be clearly seen with sinography. When a cyst is suspected, abdominal USG, CT scanning, or MRI can be performed to visualize the cyst. Vesicourachal diverticulum can be seen on VCUG, USG, or CT scan.⁹

Management

The management of urachal anomalies depends on the type of anomaly. In the case of urachal infection with abscess, early drainage is performed along with antibiotic administration. Urachal infection is initially treated with broad-spectrum antibiotics (7-10 days) followed by resection. After the infection is resolved, complete excision is performed for patent urachus, including the bladder cuff. It is important to remove all anomalous tissue to avoid recurrence, stone formation, and prevent malignant transformation.¹⁰

For patent urachus, urachal cyst, urachal sinus, or urachal diverticulum that requires correction, the patient is positioned in the supine position. If possible, a small catheter with a guide wire is placed through the patent urachus. If there is no drainage, the tract can be stained with methylene blue for further identification. A Foley catheter should be inserted into the bladder and the bladder should be inflated with sterile saline to attach the anterior wall of the bladder to the abdominal wall, and to do this, the peritoneum is pressed towards the cephalad direction. The urachus can be reached by a vertical incision on the midline or a transverse infraumbilical incision up to one-half to two-thirds of the distance from the umbilicus to the pubic symphysis. Although the transverse infraumbilical incision provides a perfect opening, the midline vertical incision along the urachus can be more direct and also widening towards the umbilicus can be done with better cosmetic results, which is usually necessary because of the difficulty in displaying the end part of the umbilicus from the urachus or for other necessary purposes. The rectus fascia is opened and the dome of the bladder is identified. The urachus is identified and separated. Once the proximal part of the urachus is opened, complete resection is then performed using a small knife to prevent the formation of residual diverticula. The bladder is then closed in two layers. Dissection is performed and then continued up to the umbilicus. The surgery is facilitated by identifying the appropriate dissection plane between the posterior peritoneum to the urachus and the posterior rectus fascia, which is the anterior urachus. At the same site, the umbilical artery also passes through which will then be ligated both proximally to the bladder wall and distally to the umbilicus.¹⁰

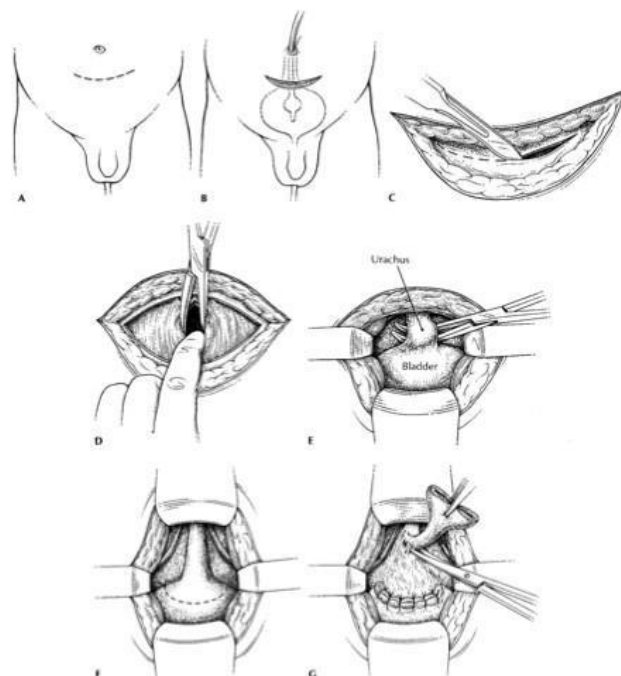


Figure 9. Urachus Surgical Technique.

Complications

The complications of each type of urachus are different:

1. Patent Urachus

Complications of patent urachus include recurrent omphalitis, cystitis, pyelonephritis, calcification, and carcinoma.¹¹

2. Urachal Cyst

Complications of an infected urachal cyst include intraperitoneal rupture causing necrotizing fasciitis.¹²

3. Urachal Sinus

Urachal sinus can cause complications such as abscesses, stones, and gas formation as reported in our case. Other reported complications include rupture into the peritoneal cavity causing peritonitis, uracho-colon fistula, and neoplastic transformation. The risk of urachal malignancy in adults is high and has a poor prognosis.¹³

4. Vesicourachal Diverticulum

Complications of vesicourachal diverticulum include chronic bladder obstruction, urinary tract infection, intraurachal stone formation, and increased incidence of adenocarcinoma after puberty.¹⁴

Prognosis

Urachal anomalies generally do not have significant morbidity and mortality. Without other serious congenital anomalies, the prognosis for urachal anomalies is good, except in cases of adenocarcinoma where the prognosis is poor.

However, if a serious congenital anomaly is found along with urachal remnants, the prognosis is poor. Patients with surgically treated urachal remnants generally have a good condition and quick recovery. Complications of urachal remnants such as adenocarcinoma have a poor prognosis.¹¹

Reference

1. Nimmonrat A, Na-Chiangmai W, Muttarak M. Urachal abnormalities: clinical and imaging features. *Singapore Med J*. 2008 Nov;49(11):930–5.
2. Huang W-H, Yu C-C, Lee Y-H, Sung P-K, Chou C-P, Huang J-K. Urachal Anomalies: 10-Years' Experience at Kaohsiung Veterans General Hospital. *中華民國泌尿科醫學會雜誌*. 2002;13(2):63–7.
3. Sulak O, Cankara N, Malas MA, Cetin E, Desdicioglu K. Anatomical development of the normal urachus during the fetal period. *Saudi Med J*. 2008;29(1):30.
4. Begg RC. The urachus: its anatomy, histology and development. *J Anat*. 1930;64(Pt 2):170.
5. Frimberger D. Bladder anomalies in children. *Campbell-Walsh Urol*. 2007;3579–80.
6. Ekwueme KC, Parr NJ. Infected urachal cyst in an adult: a case report and review of the literature. *Cases J*. 2009;2(1):1–3.
7. Das JP, Hutchinson B, Murphy JM, McCarthy P. Pathology of Persistent Urachal Remnants: A Pictorial Review. In *European Congress of Radiology-ECR 2014*; 2014.
8. Austin PF. Umbilical and urachal anomalies. *Pediatr Urol Surg Complicat Manag*. 2015;116–22.
9. Kim SH. *Radiology illustrated: urology*. Springer Science & Business Media; 2011.
10. Frangandreas G, Flaris N, Tsantilas D, Spiridis C, Pezikoglou H, Gerasimidis T. Large serous urachal cyst in an adult. *Hippokratia*. 2002;6(4):167–70.
11. Tanagho E. *Anatomy of the Genitourinary Tract*. In: McAninch JW, Lue T, editors. *Smith & Tanagho's General Urology*. 19th ed. McGraw Hill; 2020.
12. Qureshi K, Maskell D, McMillan C, Wijewardena C. An infected urachal cyst presenting as an acute abdomen—A case report. *Int J Surg Case Rep*. 2013;4(7):633–5.
13. Yalawar RS, Khanapur R, Patil LS, Kulkarni A. Infected urachal sinus presenting as infraumbilical mass: A Case report and review of literature. *IOSR J Dent Med Sci*. 2014;13(8):12–5.
14. Özbülbul NI, Dagli M, Akdogan G, Ölçer T. CT urography of a vesicourachal diverticulum containing calculi. *Diagnostic Interv Radiol*. 2010;16(1):56.